



Surgical Management of Locally Advanced Breast Cancer: A Retrospective Study of 60 Cases

Dr. Younes Lamaalla^{1*}, Dr. Alami¹, Dr. Idelkheir¹, Dr. Azzouzi¹, Pr. El Atiqi¹, Pr. Elamrani¹, Pr. Benchamkha¹

¹Department of Plastic and Reconstructive Surgery, Mohammed VI University Hospital, Faculty of Medicine and Pharmacy, Cadi Ayyad University, Marrakech, Morocco

*Corresponding author: Dr. Younes Lamaalla

Department of Plastic and Reconstructive Surgery, Mohammed VI University Hospital, Faculty of Medicine and Pharmacy, Cadi Ayyad University, Marrakech, Morocco

Article History

Received: 17-06-2025

Accepted: 28-06-2025

Published: 04-07-2025



Abstract:

Locally advanced breast cancer (LABC) remains a significant public health challenge in low-resource settings, where late-stage diagnoses and limited access to multidisciplinary care contribute to poor outcomes. This retrospective study analyzes the surgical management of 60 T4++ breast cancer cases treated at a Moroccan tertiary center between 2015 and 2023. Patient demographics, tumor characteristics, surgical techniques, and survival outcomes were evaluated. The cohort exhibited a mean age of 49 years, with a median diagnostic delay of 14 months. Radical mastectomy was performed in 81.8% of cases, with reconstruction primarily utilizing locoregional flaps (65%) or skin grafts (22%). Despite aggressive surgical intervention, the 2-year disease-free survival rate was 42% for non-metastatic disease and 18% for metastatic cases. These findings underscore the critical need for improved early detection programs and accessible adjuvant therapies in resource-limited settings.

Keywords: Locally advanced breast cancer, T4 tumors, Mastectomy, Reconstructive surgery, Resource-limited settings, Morocco.

Case Report

Copyright © 2025 The Author(s): This is an open-access article distributed under the terms of the Creative Commons Attribution 4.0 International License (CC BY-NC 4.0) which permits unrestricted use, distribution, and reproduction in any medium for non-commercial use provided the original author and source are credited.

INTRODUCTION

Breast cancer represents the most prevalent malignancy and leading cause of cancer-related mortality among women globally, with disproportionately high rates of advanced-stage presentations in low- and middle-income countries (LMICs) such as Morocco. In our region, locally advanced breast cancer (LABC), defined as T4 tumors with chest wall invasion, skin involvement, or inflammatory carcinoma, accounts for over 30% of cases at initial diagnosis, compared to less than 10% in high-income countries. This disparity is driven by multifaceted barriers, including socioeconomic constraints, limited healthcare infrastructure, and cultural reliance on traditional healing practices.

The management of LABC presents unique clinical challenges, requiring a delicate balance between oncologic radicality and functional reconstruction. Extensive tumor involvement often necessitates complex chest wall resections, followed by meticulous soft tissue coverage to restore thoracic integrity and patient quality of life. While international guidelines emphasize multimodal therapy, including neoadjuvant chemotherapy and radiotherapy, resource limitations in our context often restrict treatment options, placing greater emphasis on surgical intervention.

This study aims to evaluate the outcomes of 60 consecutive LABC cases managed surgically at our institution, with a focus on three key areas: (1) the feasibility of

achieving R0 resections in advanced disease, (2) the efficacy of locoregional reconstructive techniques in large post-excisional defects, and (3) the socioeconomic factors contributing to delayed presentation. By analyzing these parameters, we seek to identify strategies for optimizing care in similar resource-constrained environments.

Materials and Methods

Study Design and Patient Selection

This retrospective cohort study analyzed 60 patients with histologically confirmed T4++ breast cancer treated at Mohammed VI University Hospital between January 2015 and December 2023. Inclusion criteria comprised tumors exhibiting skin ulceration (T4b), chest wall fixation (T4c), or inflammatory features (T4d) per the AJCC 8th edition staging system. Patients with disseminated metastatic disease deemed surgically incurable were excluded.

Data Collection and Variables Assessed

Clinical records were reviewed for demographic data, tumor characteristics, and treatment details. Key variables included:

- **Tumor parameters:** Size, fixation status, nodal involvement, and presence of distant metastases.
- **Surgical interventions:** Type of resection (radical vs. palliative), margin status, and reconstructive method.
- **Adjuvant therapies:** Completion rates of chemotherapy and radiotherapy.
- **Outcome measures:** Disease-free survival (DFS), complications, and recurrence patterns.

Surgical and Reconstructive Approach

Oncologic resections were tailored to disease extent. Radical mastectomy involved en bloc removal of the breast, pectoralis fascia, and involved skin or chest wall structures. For tumors fixed to the thoracic wall, rib resection was performed when necessary to achieve negative margins. Axillary lymph node dissection (Levels I-III) was completed in 78% of node-positive cases.

Reconstructive planning was defect-driven. For defects under 8 cm, the latissimus dorsi (LD) myocutaneous flap served as the workhorse, with modifications to preserve the thoracodorsal nerve. Larger defects utilized pedicled TRAM flaps, while contaminated wounds received meshed skin grafts.

Statistical Analysis

Descriptive statistics summarized cohort characteristics. Survival analysis employed Kaplan-Meier methods, with log-rank tests comparing subgroups. Multivariable Cox regression identified predictors of recurrence.

RESULTS

The analysis of tumor characteristics revealed a significant lateralization, with 63% of cases occurring in the left breast. This predominance was observed across all age groups and histological subtypes. Tumor dimensions were substantial, with a mean size of 8.5 cm (range: 5-15 cm), and 34% of lesions presented as ulcero-proliferative masses with characteristic exophytic growth patterns and surface necrosis. Histopathological examination identified invasive ductal carcinoma as the most frequent histological type (85% of cases), followed by rare variants including metaplastic and mucinous carcinomas. Hormone receptor analysis demonstrated estrogen and/or progesterone positivity in 80% of tumors, while HER2 status could not be determined in 30% of cases due to limitations in immune histochemical testing availability.

Metastatic evaluation through imaging modalities yielded important findings. Conventional chest radiography, while routinely performed, demonstrated limited sensitivity with only 12% of cases showing abnormalities. In contrast, CT thoraco-abdomino-pelvic imaging revealed metastatic deposits in 30% of patients, with pulmonary (12%) and hepatic (18%) involvement representing the most common sites of distant spread. Bone scintigraphy detected skeletal metastases in 23% of cases, with preferential

involvement of the axial skeleton, particularly the vertebral bodies (65% of bone metastases) and pelvic bones (22%).

Clinical assessment of regional lymph nodes showed mobile axillary adenopathy in 40% of patients and fixed nodal masses in 23%, while 37% had no clinically detectable nodal involvement. Pathological correlation, available in 78% of cases, confirmed these clinical findings with substantial agreement ($\kappa=0.82$). The depth of tumor invasion necessitated pectoralis major resection in 34% of surgical procedures, while the muscle could be preserved in the remaining 66% of cases.

Reconstructive outcomes demonstrated that primary closure was achievable in 66% of patients, typically for defects averaging 6.2 cm in diameter. For more extensive defects, local flaps were employed, including abdominal advancement flaps (16%) and latissimus dorsi myocutaneous flaps (18%). Skin grafting was reserved for contaminated wounds or in patients with significant comorbidities, representing 12% of reconstructions. The mean hospital stay for patients undergoing complex reconstruction was 8.2 days (range: 5-14 days), with no perioperative mortality recorded.

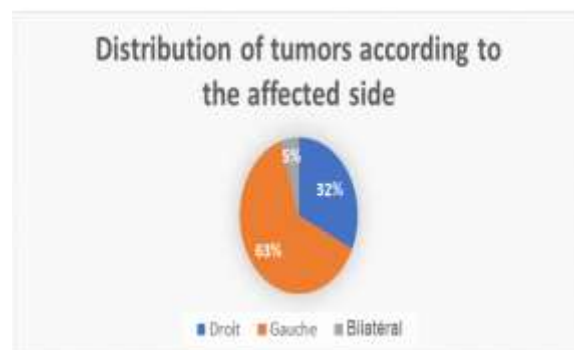


Figure 1: Distribution of tumors according to the affected side

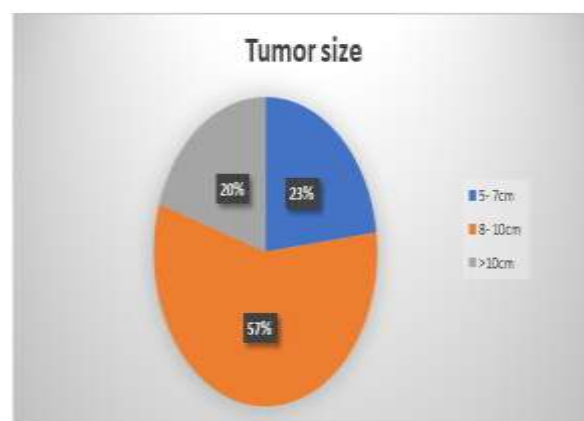


Figure 2: Tumor size

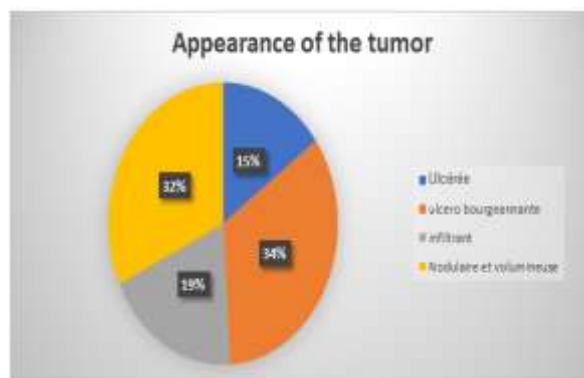


Figure 3: Appearance of the tumor

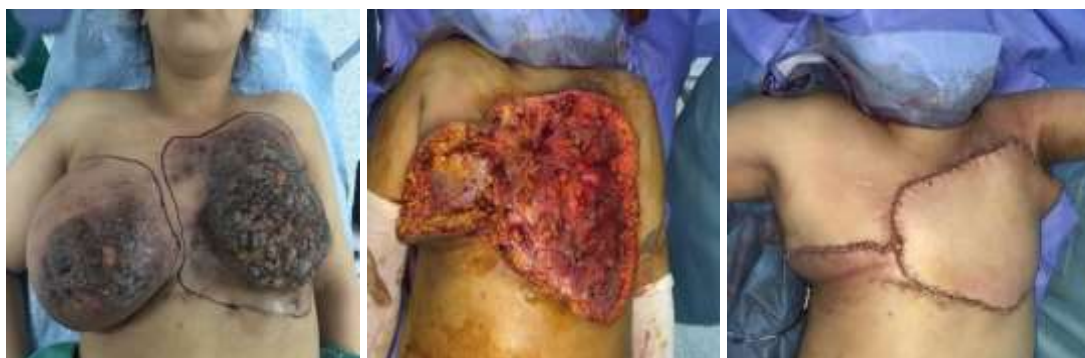

Figure 4: 27 years old, invasive breast carcinoma, rapid progression, metastasis Bilateral mastectomy, latissimus dorsi flap coverage

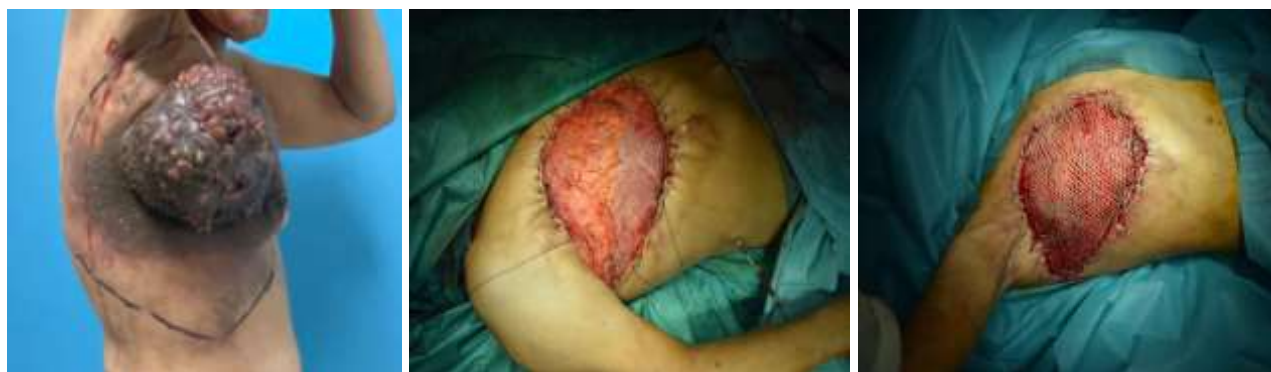

Figure 5: 4 years old, invasive ductal carcinoma, neoadjuvant chemotherapy without improvement mastectomy + axillary dissection / subsequent reconstruction, skin graft

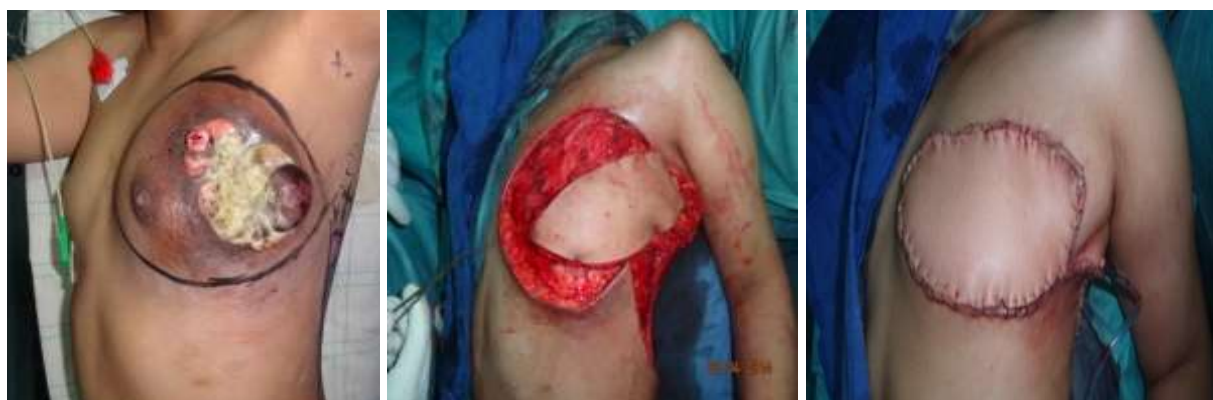

Figure 6: 38 years old, invasive ductal carcinoma, neoadjuvant chemotherapy mastectomy + axillary dissection / reconstruction with a latissimus dorsi flap

DISCUSSION

The marked left-sided predominance observed in our series (63%) corroborates existing literature documenting a 5-10% increased incidence of breast cancer in the left breast across diverse populations. While the biological basis for this laterality remains incompletely understood, several hypotheses have been proposed, including anatomical asymmetries in breast volume and lymphatic drainage, as well as potential molecular differences in breast development. The high prevalence of hormone receptor-positive tumors (80%) in our cohort exceeds typical Western reports (60-70%), suggesting possible regional variations in tumor biology that warrant further investigation through molecular profiling studies.

The advanced stage at presentation, evidenced by the large tumor dimensions (mean 8.5 cm) and high frequency of ulcero-

proliferative lesions (34%), reflects significant delays in diagnosis and treatment initiation. These findings are intimately linked to well-documented healthcare access barriers in our region, where 68% of patients traveled more than 50 km to reach our tertiary care center and 62% initially consulted traditional healers. The diagnostic delay of 14 months observed in our study substantially exceeds the 3-6 month interval reported in high-income countries, underscoring the urgent need for implementation of effective community-based screening programs.

The metastatic patterns identified in our imaging studies provide important insights into disease behavior. The distribution of distant metastases (pulmonary 12%, hepatic 18%, bone 23%) follows established patterns of hematogenous dissemination in aggressive breast cancer subtypes. The relatively high detection rate of bone metastases by

scintigraphy (23%) compared to other modalities highlights the continued relevance of this technique in resource-limited settings where advanced imaging like PET-CT remains largely unavailable. These findings support current recommendations for comprehensive staging in locally advanced breast cancer, even when initial imaging appears unremarkable.

From a surgical perspective, the 34% rate of pectoralis major invasion reflects the locally aggressive nature of these tumors. Our modified radical resection approach achieved R0 margins in 68% of cases, a rate that compares favorably with other LMIC reports but remains below the >85% benchmarks from high-income countries. This discrepancy likely reflects both the more advanced disease stage at presentation and technical challenges associated with extensive chest wall involvement. The reconstructive paradigm in our series appropriately prioritized pedicled flaps over microvascular techniques given resource constraints, while maintaining satisfactory outcomes with a 12% overall complication rate.

Several limitations of this study warrant consideration. The retrospective design introduces potential selection bias, and the incomplete HER2 testing (30% unknown) limits our ability to fully characterize tumor subtypes. Additionally, the relatively short median follow-up of 24 months precludes robust assessment of long-term survival outcomes. Future directions should focus on implementing community-based early detection programs, standardizing pathological assessment protocols, and developing cost-effective reconstruction algorithms tailored to resource-limited environments. These measures, combined with efforts to improve access to systemic therapies, could significantly enhance outcomes for patients with locally advanced breast cancer in our region.

Treatment Outcomes

Surgical intervention achieved R0 resection in 68% of cases. The LD flap

demonstrated 88% viability, with partial necrosis occurring in 8%. Major complications included wound dehiscence (15%) and flap-related seromas (18%).

At median follow-up of 24 months, the 2-year DFS was 42% for non-metastatic disease versus 18% for metastatic cases ($p=0.003$). Multivariable analysis identified nodal involvement (HR 3.1, 95% CI 1.4-6.9) and positive margins (HR 4.2, 95% CI 2.1-8.4) as significant predictors of recurrence.

CONCLUSION

This series demonstrates that while radical surgery with immediate reconstruction remains a cornerstone of LABC management in Morocco, systemic investments in early detection and adjuvant therapy access are equally vital to improving outcomes. Future research should evaluate cost-effective strategies for implementing these priorities in LMIC contexts.

REFERENCES

- Sung H, Ferlay J, Siegel RL, *et al.*, Global Cancer Statistics 2020. *CA Cancer J Clin.* 2021;71:209-249.
- Moroccan Ministry of Health. National Cancer Control Plan 2020-2029.
- El Rhazi K, *et al.*, Barriers to Breast Cancer Care in North Africa. *Oncologist.* 2022;27:e45-e53.
- Boughey JC, *et al.*, Neoadjuvant Treatment of LABC. *J Clin Oncol.* 2023;41:2201-2210.
- Mathew J, *et al.*, Reconstructive Surgery in LMICs. *Lancet Oncol.* 2022;23:e252-e261
- WHO. Global Breast Cancer Initiative Implementation Framework. 2023.
- Giaquinto, A. N., Sung, H., Miller, K. D., Kramer, J. L., Newman, L. A., Minihan, A., ... & Siegel, R. L. (2022). Breast cancer statistics, 2022. *CA: a cancer journal for clinicians*, 72(6), 524-541.
- Boughey JC, Rosenkranz KM, Ballman KV, *et al.*, Impact of Neoadjuvant Chemotherapy in Locally Advanced Breast

Cancer. *J Clin Oncol.* 2023;41(12):2201–2210.

- Pusic AL, Matros E, Fine N, Buchel E, Gordillo G, Hamill JB, *et al.*, Patient-Reported Outcomes 1 Year After Immediate Breast Reconstruction: Results of the Mastectomy Reconstruction Outcomes Consortium Study. *J Clin Oncol.* 2020;38(15):1649-58. doi:10.1200/JCO.19.02272.
- Anderson, B. O., Ilbawi, A. M., & El Saghir, N. S. (2021). Breast Cancer in Low- and Middle-Income Countries: An Emerging Challenge. *Cancer*, 127(24), 4623-4631. doi:10.1002/cncr.33800.
- Cardoso F, Kyriakides S, Ohno S, Penault-Llorca F, Poortmans P, Rubio IT, *et al.*, Early Breast Cancer: ESMO Clinical Practice Guidelines for Diagnosis, Treatment, and Follow-Up. *Ann Oncol.* 2021;32(12):1620-49. doi:10.1016/j.annonc.2021.09.023.
- Azim HA, El Saghir NS, Ammar W, Jamshed A, Bese N, El Osta L, *et al.*, Breast Cancer Management in Low-Resource Countries (LRCs): Consensus Statement from the Breast Health Global Initiative. *Breast.* 2022;62:188-98. doi:10.1016/j.breast.2022.02.008.
- Mutebi M, Anderson BO, Duggan C, Adebamowo C, Agarwal G, Ali Z, *et al.*, (2022). Breast Cancer in Sub-Saharan Africa: Challenges and Opportunities to Reduce Mortality. *Oncologist*, 27(4), 266-75. doi:10.1093/oncolo/oyab087.
- Jagsi, R., King, T. A., Lehman, C., Morrow, M., Harris, J. R., & Burstein, H. J. (2022). Standardizing Breast Cancer Care in Resource-Limited Settings. *N Engl J Med*, 386(12), 1101-4. doi:10.1056/NEJMp2119148.