

Compressing Inter-Hepato-Thoracic Hydatid Cyst Revealed by Dyspnea: A Case Report

S. Bah^{1*}, M. K. Diakité¹, S. M. Navee¹, B. Nzingoula¹, B. Odoulou¹, O. Ettachfini¹

¹Arrazi Hospital – Mohammed VI University Hospital Center of Marrakech, Morocco

*Corresponding author: S. Bah

Arrazi Hospital – Mohammed VI University Hospital Center of Marrakech, Morocco

Article History

Received: 17-07-2025

Accepted: 24-07-2025

Published: 01-08-2025



Abstract:

We report the case of a 67-year-old patient presenting with progressive dyspnea. Initial chest imaging revealed a large right-sided pleural effusion. A thoracoabdominal CT scan identified a large inter-hepato-thoracic hydatid cyst compressing adjacent structures. This case illustrates a rare localization of hydatid disease with significant thoracic impact.

Keywords: Hydatid cyst, Pleural effusion, Thoracic compression, Echinococcosis, CT scan.

Case Report

Copyright © 2025 The Author(s): This is an open-access article distributed under the terms of the Creative Commons Attribution 4.0 International License (CC BY-NC 4.0) which permits unrestricted use, distribution, and reproduction in any medium for non-commercial use provided the original author and source are credited.

INTRODUCTION

Hydatid disease is a cosmopolitan parasitic infection caused by *Echinococcus granulosus*, primarily affecting the liver and lungs. However, unusual localizations may occur, particularly in thoracoabdominal transitional regions, sometimes posing a diagnostic challenge. Human transmission mainly results from the ingestion of parasite eggs excreted by canines, making it more prevalent in rural and livestock-farming areas. Clinical manifestations depend on the cyst's size and location, and compressive thoracic forms are rare but potentially severe [1]. Imaging, especially computed tomography (CT), is the reference tool for detecting, characterizing, and evaluating the extent of hydatid cysts.

Case Report

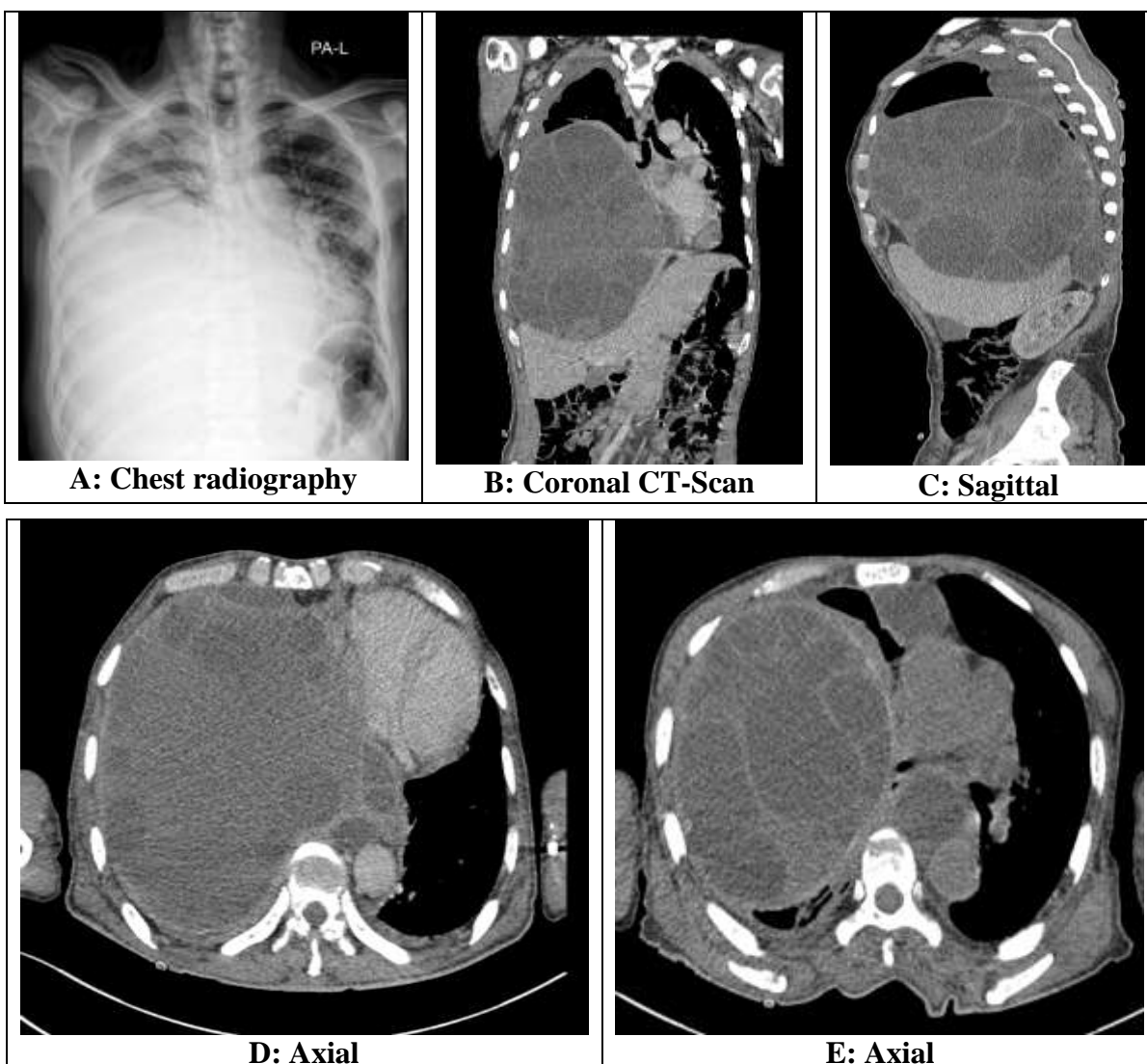
We report the case of a 67-year-old male patient, with no significant medical history, who presented with progressively

worsening dyspnea evolving over several weeks. Clinical examination revealed dullness to percussion at the right lung base and decreased breath sounds on the same side. A chest radiograph revealed a large right-sided pleural effusion, with no evidence of mediastinal shift.

A contrast-enhanced thoracoabdominal-pelvic CT scan was performed as part of the etiological workup. It revealed a large inter-hepato-thoracic hydatid cyst, measuring approximately 20 x 17 x 23 cm. The cyst was well-demarcated, thin-walled, multivesicular, displacing the right diaphragmatic dome downward and compressing the anterior and middle mediastinal structures upward and to the left. The liver was displaced inferiorly, with no additional hepatic lesions identified beyond the cyst. The imaging findings were consistent with a CE2 stage hydatid cyst according to the WHO-IWGE classification [2].

No other hydatid localizations were found on abdominopelvic imaging. The pleural effusion was moderate on CT, without

signs of superinfection. Hydatid serology was performed and returned positive.



DISCUSSION

Inter-hepato-thoracic localization is extremely rare and may result from transdiaphragmatic migration or superior exophytic development of a hepatic cyst [3, 4]. The cyst may remain asymptomatic for a long time until it reaches a sufficient size to exert mechanical compression on adjacent structures, as in this case with the diaphragm and mediastinal components.

Thoracoabdominal CT plays a central role in lesion characterization and in assessing the extent of involvement. It is also essential

for identifying potential complications such as rupture, superinfection, or fistulization. The WHO classification of hydatid cysts guides treatment decisions and follow-up [2]. Treatment is usually surgical, particularly in compressive forms, and is often combined with dual antiparasitic therapy using albendazole and praziquantel, administered both pre- and postoperatively [5].

CONCLUSION

Atypical hydatid localizations, such as inter-hepato-thoracic forms, should be considered in cases of thoracic compressive

syndromes in endemic regions. CT imaging allows for accurate diagnosis and optimal therapeutic planning.

REFERENCES

1. Pedrosa, I., Saíz, A., Arrazola, J., Ferreirós, J., & Pedrosa, C. S. (2000). Hydatid disease: Radiologic and pathologic features and complications. *Radiographics*, 20(3), 795-817.
2. WHO Informal Working Group on Echinococcosis. International classification of ultrasound images in cystic echinococcosis for application in clinical and field epidemiological settings. *Acta Trop*. 2003;85(2), 253-261.
3. Dziri, C, Haouet, K., & Fingerhut, A. (2004). Treatment of hydatid cyst of the liver: Where is the evidence? *World J Surg*, 28(8), 731-736.
4. Sayek, I., Tirnaksiz, M. B., & Dogan, R. (2004). Cystic hydatid disease: current trends in diagnosis and management. *Surg Today*, 34(12), 987-996.
5. Stojkovic, M., & Junghanss, T. (2018). Diagnosis and clinical management of cystic echinococcosis. *BMJ*, 361, k2446.