



Nasal Reconstruction: Menick's Technique

J. Hafidi^{1*}, H. El Kamch¹, K. Benmoussa¹, K. Bennani¹, S. Charboub¹, N. Gharib¹, A. Abbasi¹, S. El Mazouz¹

¹Department of Plastic and Reconstructive Surgery, Ibn Sina Hospital of Rabat, Morocco

*Corresponding author: J. Hafidi

Department of Plastic and Reconstructive Surgery, Ibn Sina Hospital of Rabat, Morocco

Article History

Received: 07-08-2025

Accepted: 21-08-2025

Published: 01-09-2025



Abstract:

Reconstructing nasal defects poses a significant challenge for plastic surgeons. Various techniques have been proposed in the literature, but none have consistently yielded optimal aesthetic results. This article presents the case of a patient with a transfixing nasal defect successfully reconstructed using the three-stage forehead flap technique, as practiced at the Department of Reconstructive and Plastic Surgery at Ibn Sina Hospital in Rabat. **Keywords:** Nasal defect, nasal reconstruction, forehead flap. Introduction Nasal reconstruction has historically been a fundamental aspect of plastic surgery, with the forehead flap being the cornerstone technique for repair [5]. Due to its superior color and texture match, the forehead serves as an ideal donor site for nasal resurfacing. However, forehead flaps, regardless of their vascular pedicle, tend to be thicker than native nasal skin. Traditionally, forehead flaps are transferred in two stages. In the first stage, the frontalis muscle and subcutaneous tissue are partially excised distally, and the flap is inset into the recipient site. Three weeks later, in the second stage, the pedicle is divided. However, this approach has limitations, including incomplete flap thinning and the risk of necrosis, particularly in smokers and complex nasal reconstructions. To address these issues, an additional surgical stage has been incorporated between flap transfer and pedicle division [2].

Keywords: Nasal reconstruction, Menick's technique, Reconstructive surgery, Transfixing nasal defect, Nasal tumor.

Case Report

Copyright © 2025 The Author(s): This is an open-access article distributed under the terms of the Creative Commons Attribution 4.0 International License (CC BY-NC 4.0) which permits unrestricted use, distribution, and reproduction in any medium for non-commercial use provided the original author and source are credited.

INTRODUCTION

Nasal reconstruction remains one of the most challenging endeavors in plastic and reconstructive surgery due to the nose's central position on the face and its complex three-dimensional anatomy. Beyond restoring nasal function, achieving satisfactory aesthetic outcomes is of paramount importance, as even subtle imperfections are readily visible. Over the years, various reconstructive techniques have been described, ranging from local flaps and skin grafts to regional and free flaps. Among these, the forehead flap has historically stood out as the cornerstone procedure for nasal resurfacing, owing to its robust vascularity, versatility, and excellent color and texture match with nasal skin.

Traditionally, forehead flaps are performed in two stages, involving initial

transfer followed by pedicle division. While effective, this method has limitations, particularly with respect to flap thickness, contour definition, and risk of necrosis in patients with comorbidities or in complex defects. To address these shortcomings, Menick introduced a three-stage modification that incorporates an intermediate operation between flap transfer and pedicle division. This additional stage allows for safe flap thinning, precise cartilage grafting, and improved contour refinement, ultimately enhancing both aesthetic and functional results.

In this article, we report a case of a transfixing nasal defect following excision of basal cell carcinoma, reconstructed using the three-stage forehead flap technique at the Department of Reconstructive and Plastic Surgery, Ibn Sina Hospital, Rabat. This case

illustrates the reliability and versatility of the technique in addressing complex nasal defects while ensuring superior long-term outcomes.

Case Report

A 72-year-old patient with no significant medical history was admitted to the Department of Reconstructive and Plastic Surgery at Ibn Sina Hospital in Rabat for the management of an infiltrative basal cell carcinoma of the nose. Tumor excision with a 1 cm margin resulted in a transfixing defect at the nasal tip and wing. Reconstruction was performed using the three-stage forehead flap technique.

DISCUSSION

Since its modification by F. Menick [1-5], the three-stage forehead flap has become the preferred technique for nasal defect reconstruction. This method is reliable and allows for the repair of both superficial and transfixing defects. The surgical approach involves three distinct stages, performed at three-week intervals.

First Stage: Preoperative planning is conducted on the morning of surgery. The supratrochlear artery, serving as the flap's vascular pedicle, is first identified. The nasal defect is then traced onto paper and transferred onto the forehead, ensuring proper flap rotation alignment. A distal extension of the flap is designed for deep plane reconstruction.

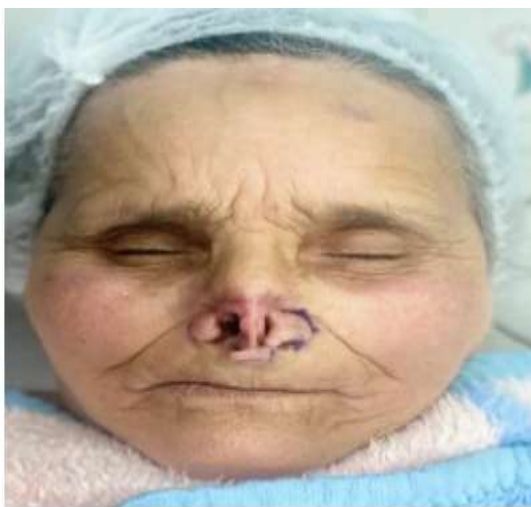

Figure 1: After excision of a basal cell carcinoma of the nose, we notice a transfixing defect in the tip and the alar wing

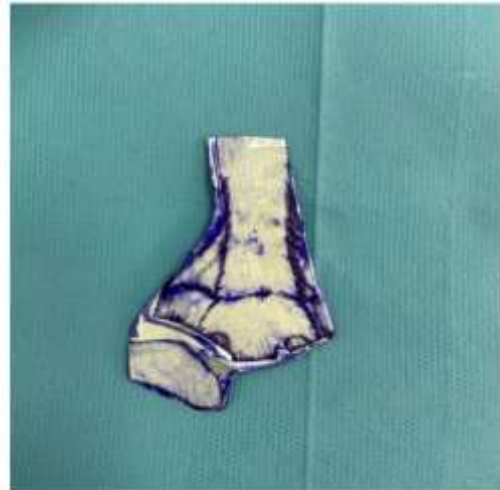


Figure 2: The defect is marked on aluminum paper and redrawn in the forehead

After complete excision of the nasal subunits requiring reconstruction, a full-thickness forehead flap, including the frontalis muscle, is elevated. The flap should be rotated toward the nasal side to facilitate movement and reduce tension on the eyebrow. Deep plane reconstruction begins with folding and suturing the distal portion of the flap using absorbable sutures. The flap is then inset into the recipient site (nasal tip and nostril wing). The forehead donor site is closed with careful undermining. To minimize secretions and bleeding while improving patient comfort, the deep aspect of the pedicle may be skin-grafted. At the end of the first stage, the flap remains thick. Excess frontalis muscle is excised in the second stage to refine nasal contours.

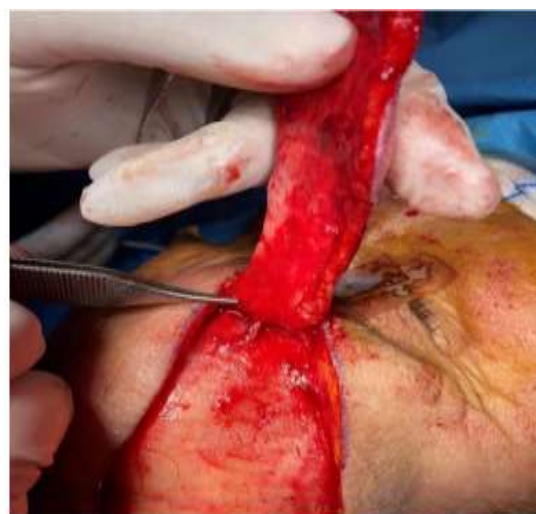

Figure 3: The flap is elevated in full thickness, after excision of the hemi tip and alar wing

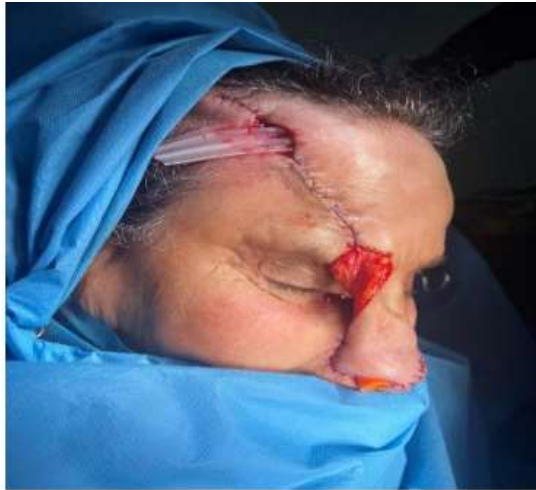

Figure 4: Immediate post-operative aspect of the 1st Step

Second Stage: Three weeks postoperatively, the flap is elevated in a subcutaneous plane while preserving the frontalis muscle and the distal extension used for deep plane reconstruction. Excess muscle is excised based on the desired nasal thickness. A conchal cartilage graft is placed at the nasal tip to enhance support and definition. The flap is then sutured, incorporating Capiton-type stitches to refine nasal contours, particularly the nostril wing. Pedicle division is postponed until the third stage.

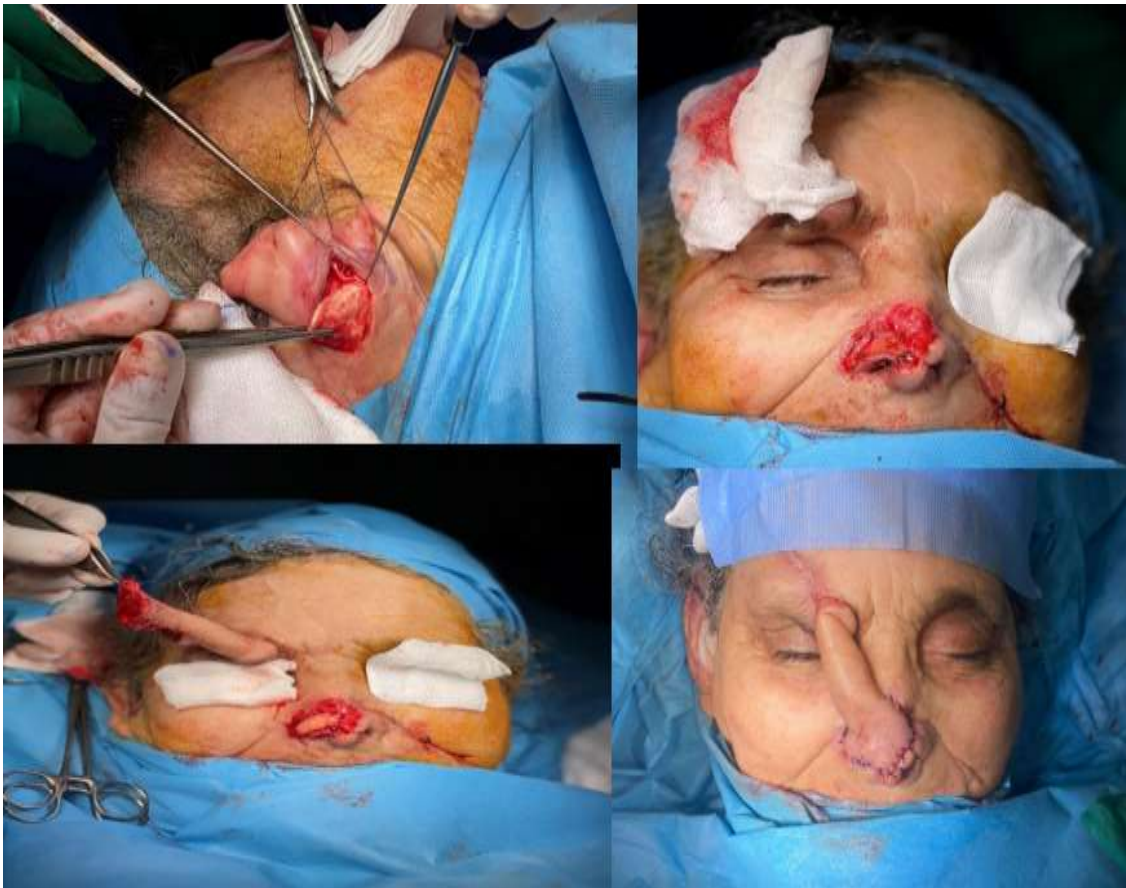

Figure 5: Cartilage graft after elevating and thinning the flap, leaving the distal extension destined to reconstruct the deep plane and Immediate post-operative aspect of the 2nd step, the aesthetic lines of the nose was marked using some Capiton-type stitch

Third Stage: In the final stage, the pedicle is divided, and the distal portion of the flap covering the defect is fully healed. Skin resection is performed to ensure precise alignment with the nasal subunits requiring

reconstruction, specifically the hemi-tip and nostril wing. The eyebrow is repositioned to match its contralateral counterpart, as the flap pedicle often causes downward displacement.

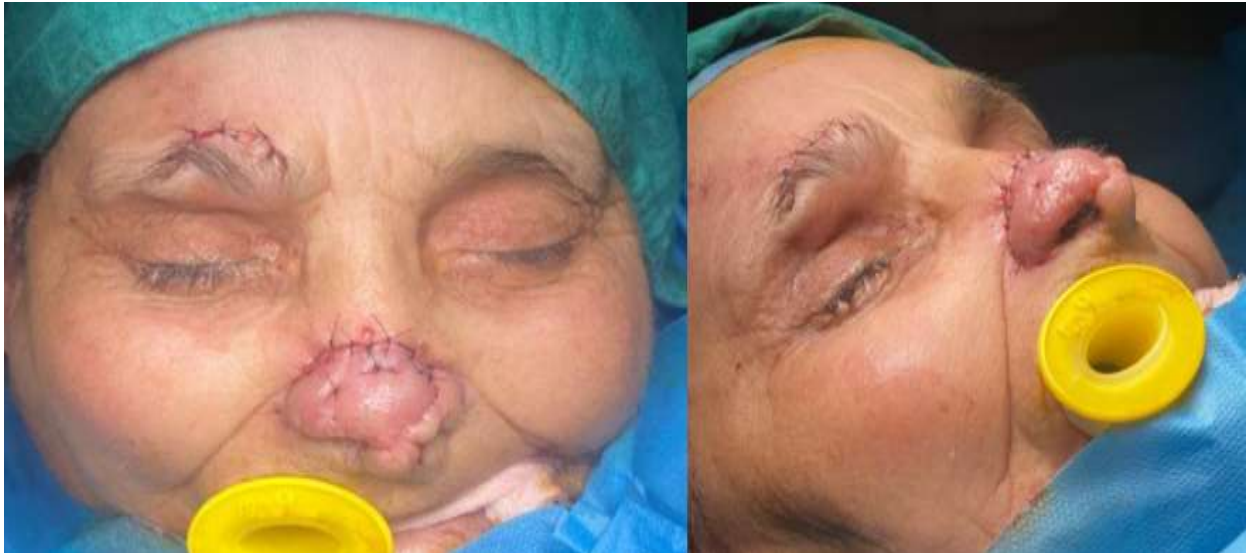

Figure 6: Immediate post-operative aspect of the 3rd and final step

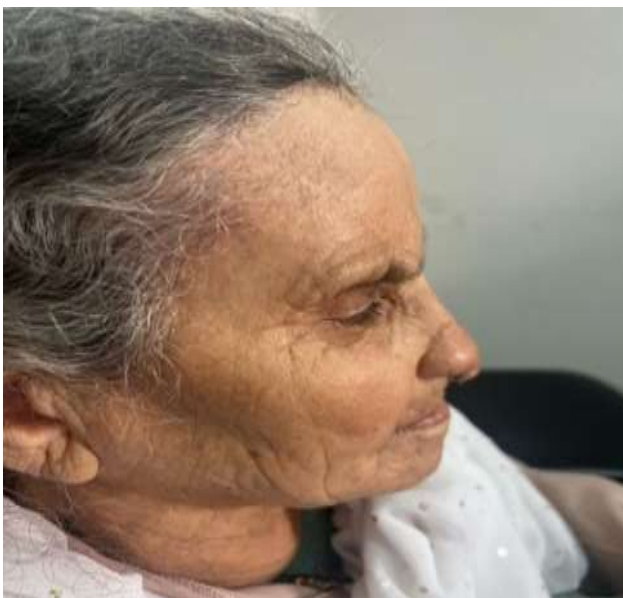

Figure 7: Final result 2 years later

CONCLUSION

The aesthetic outcomes of the three-stage forehead flap are excellent. Retaining the frontalis muscle minimizes fibrosis and flap retraction. The second stage allows for muscle thinning, cartilage graft placement, and nasal contour definition. The final refinement occurs after pedicle division in the third stage. The three-stage forehead flap remains the most effective method for reconstructing all types of nasal defects, whether transfixing or superficial, involving a single subunit or the entire nose. It significantly surpasses other techniques in terms of aesthetic results.

REFERENCES

1. Menick, F. J. (2010). Nasal reconstruction. *Plastic and Reconstructive Surgery*, 125(4), 138e-150e.
2. Menick, F. J. (2002). A 10-year experience in nasal reconstruction with the three-stage forehead flap. *Plastic and Reconstructive Surgery*, 109(6), 1839-1855.
3. Menick, F. J. (2009). Nasal reconstruction with a forehead flap. *Clinics in Plastic Surgery*, 36(3), 443-459.
4. Menick, F. J. (2006). A new modified method for nasal lining: the Menick technique for folded lining. *Journal of Surgical Oncology*, 94(6), 509-514.
5. Menick, F. J. (2004). Nasal reconstruction: forehead flap. *Plastic and Reconstructive Surgery*, 113(6), 100e-111e.
6. Brian, C., Travis, T., & Patrik, P. Paramedian forehead flap technique for nasal reconstruction. *Atlas of Open Access Surgery in Otorhinolaryngology and Head and Neck Surgery*.
7. El Mazouz, S. (2021). The three-stage forehead flap: A gold standard in nasal reconstruction. *Sch J Appl Med Sci*, 9(10), 1515-1519.