

## Fat Grafting in Eye Enucleation

Dr. L. Idelkheir<sup>1\*</sup>, Prof. O. Elatiqui<sup>1</sup>, Prof. Belghmaidi<sup>1</sup>, Dr. Z. Alami<sup>1</sup>, Dr. Y. Lamaalla<sup>1</sup>, Prof. S. Boukind<sup>1</sup>, Prof. D. Laamrani<sup>1</sup>, Prof. Y. Benchamkha<sup>1</sup>

<sup>1</sup>Reconstructive and Aesthetic Surgery Department in Collaboration with the Ophthalmology Department, CHU Med VI, Marrakech, Morocco

\*Corresponding author: Dr. L. Idelkheir

Reconstructive and Aesthetic Surgery Department in Collaboration with the Ophthalmology Department, CHU Med VI, Marrakech, Morocco

### Article History

Received: 05-05-2025

Accepted: 28-06-2025

Published: 02-07-2025



### Abstract:

We conducted a retrospective study involving 8 patients treated between January 2019 and January 2023 to assess the effectiveness of autologous fat grafting for filling orbital cavities in patients who underwent enucleation. Fat grafting was performed in one or more surgical stages depending on individual needs. All patients showed noticeable aesthetic improvement without major complications. No cases of rejection or infection were observed. Fat grafting is a simple, effective, and minimally invasive alternative for restoring orbital volume after enucleation, especially in resource-limited settings.

**Keywords:** Autologous Fat Grafting, Orbital Volume Restoration, Enucleation, Ocular Prosthesis Aesthetics, Retrospective Clinical Study.

### Case Report

Copyright © 2025 The Author(s): This is an open-access article distributed under the terms of the Creative Commons Attribution 4.0 International License (CC BY-NC 4.0) which permits unrestricted use, distribution, and reproduction in any medium for non-commercial use provided the original author and source are credited.

## INTRODUCTION

Enucleation, a surgical procedure to remove the eyeball while preserving orbital adnexa, results in significant orbital volume loss. This can lead to enophthalmos, altered eye appearance, superior sulcus hollowing, and eyelid disorders (entropion, ectropion).

Various reconstruction techniques have been described to address these deficits, including dermal-fat grafts, biomaterials, and, more recently, fat grafting.

Fat grafting involves injecting processed autologous fat, offering physiological volume restoration without visible scarring or allergic risk. This study shares our department's experience with this technique in enucleated patients.

## Materials and Methods

A retrospective, descriptive, and analytical study was conducted over 4 years (January 2019 – January 2023).

### 1. Inclusion Criteria:

- Patients followed in ophthalmology
- Post-enucleation cavity of traumatic, tumoral, or burn origin
- Indication for ocular prosthesis placement with orbital volume deficiency

### 2. Surgical Technique:

#### A. Liposuction:

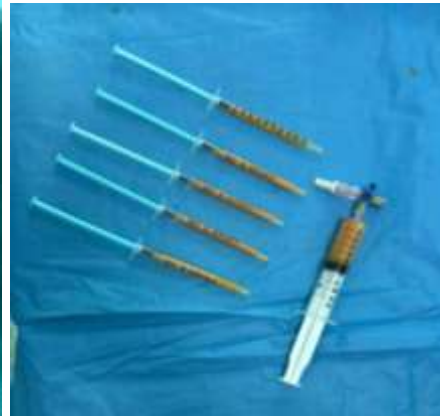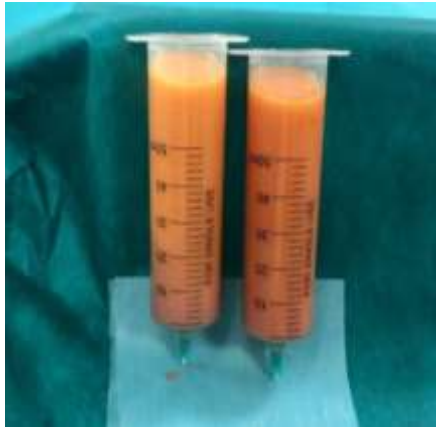
- Donor sites: subumbilical abdomen and inner knee surfaces
- Prior infiltration with Klein's solution
- Aspiration using a cannula connected to a 50 mL negative pressure syringe

#### B. Processing:

- Centrifugation at 3000 rpm for 3 minutes

#### C. Reinjection:

- Using a 1.5 mm blunt cannula
- Target planes: inferior fornix, retroseptal, and preseptal areas
- Multiplanar retrograde reinjection to optimize cell survival
- Postoperative Follow-Up



#### **D. Immediate and long-term clinical monitoring:**

Evaluated parameters: edema, bruising, infection, rejection, aesthetic result, and prosthesis adaptation.

### **3. RESULTS**

#### **Demographic and Clinical Data:**

- Sample: 8 patients (5 males, 3 females)
- Mean age: 27 years (range: 4–52 years)
- Causes of Enucleation:
  - Post-traumatic: 3 cases
  - Post-tumoral (retinoblastoma): 2 cases
  - Post-burn: 3 cases
- Average delay between enucleation and first fat grafting: 28 months (range: 24–48 months)

#### **Surgical Management:**

- Number of sessions: 1 to 3 per patient
- Average fat volume per session: 8.5 cc
- Total fat volume per patient: 4–15 cc depending on volume deficit and resorption
- Donor sites:

- Subumbilical abdomen: 6 patients
- Inner knee: 2 patients (thin individuals)

#### **Postoperative Outcomes:**

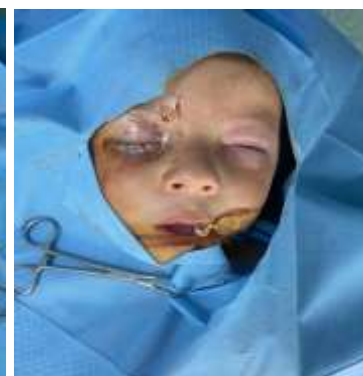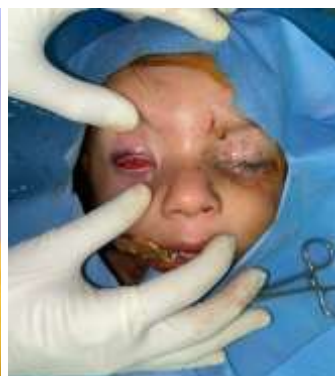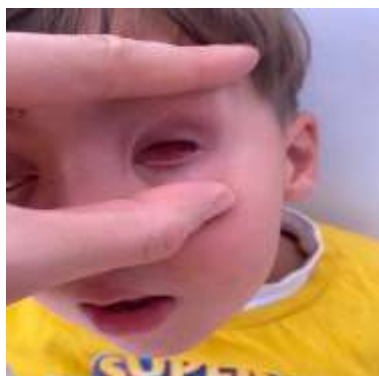- Early side effects: Moderate edema in 100% (resolved in 5–7 days), Bruising in 87% (resolved without treatment)
- No severe complications: No infections, No rejection or inflammatory reaction, No nodules or eyelid irregularities

#### **Aesthetic and Functional Results:**

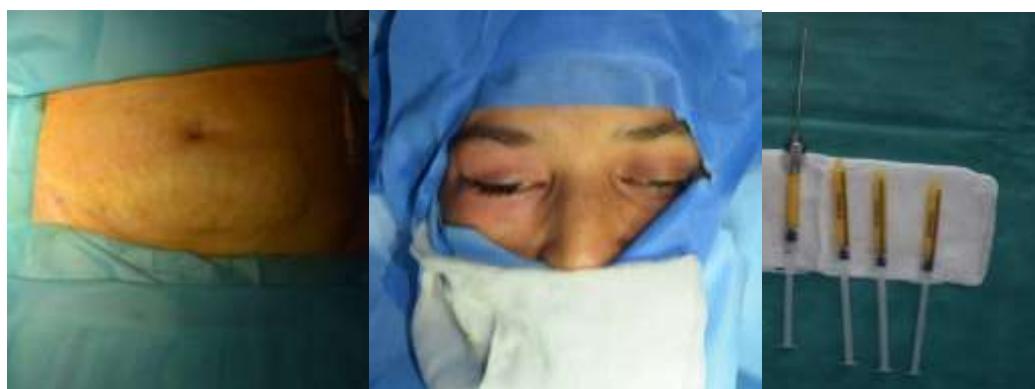- All patients successfully adapted to orbital prostheses
- Aesthetic improvement observed in all:
  - Correction of superior sulcus hollowing
  - Partial or full correction of enophthalmos
  - Improved eyelid symmetry and gaze expression
  - Patient satisfaction: rated good to excellent in all cases

### **4. Clinical Cases:**

**Case 1:** 4-year-old child, retinoblastoma; 10 cc, 2 sessions



**Case 2:** 36-year-old woman, trauma by thorn; 15 cc, 3 sessions



**Case 3:** 21-year-old male, road accident; 12 cc, 3 sessions



## DISCUSSION

Post-enucleation orbital volume loss is a major reconstructive challenge. Fat grafting offers a natural and effective approach, particularly where advanced implants are unavailable.

**Advantages:** Biocompatibility (autologous fat), Technical simplicity, Can be done under local anesthesia, Natural aesthetic result without visible scars.

Compared to biomaterials (e.g., hydroxyapatite, polymers) or fillers (e.g., hyaluronic acid), autologous fat is:

- Biologic and non-immunogenic
- Durable (though partial resorption is common)
- Aesthetically superior, especially around the orbit

It improves prosthetic adaptation by restoring retroseptal volume and prevents

mechanical complications like prosthesis migration, eyelid deformities, and altered gaze.

**Limitations:** Fat resorption: 30–50% within 6 months, requiring multiple sessions, Result variability based on age, metabolism, tissue quality, and surgeon's experience, Thin patients/children: limited fat availability, Fat performs better than fillers/biomaterials in terms of tolerance (no granulomas or allergies).

Several studies (e.g., Ozerdem *et al.*, 2013; Köller *et al.*, 2019) support the use of orbital fat grafting, reporting over 80% satisfaction and good long-term tolerance. They emphasize rigorous technique (centrifugation, micro-injections, multilayer reinjection) to optimize adipocyte survival.

## CONCLUSION

Fat grafting is a simple, safe, and reproducible technique for reconstructing post-enucleation cavities. It restores orbital volume effectively and facilitates prosthesis placement with excellent aesthetic outcomes, even in low-resource settings. Multiple sessions are often needed for durable results.

## REFERENCES

- Ozerdem, U *et al.*, (2013). Fat injection into the anophthalmic orbit to improve the aesthetic appearance of ocular prostheses. *Journal of Craniofacial Surgery*, 24(2), 508–511. <https://doi.org/10.1097/SCS.0b013e31827ffdf1>
- Köller, J *et al.*, (2019). Autologous fat grafting in orbital and periorbital reconstruction: indications, techniques, and outcomes. *Plastic and Reconstructive Surgery – Global Open*, 7(5), e2209. <https://doi.org/10.1097/GOX.00000000000002209>
- Guagliano, E *et al.*, (2016). Orbital fat grafting in anophthalmic sockets: A long-term retrospective study. *Orbit*, 35(1), 9–15. <https://doi.org/10.3109/01676830.2015.1068933>
- Khouri, R. K *et al.*, (2009). Fat grafting: a 20-year review. *Clinical Plastic Surgery*, 36(2), 241–273. <https://doi.org/10.1016/j.cps.2008.11.001>
- Koh, K. S *et al.*, (2009). Volume maintenance of injected fat grafts in the periorbital area. *Archives of Facial Plastic Surgery*, 11(4), 246–250. <https://doi.org/10.1001/archfacial.2009.4>
- Deek, N. A *et al.*, (2020). Autologous fat grafting for facial contouring and volume restoration: a comprehensive review. *Aesthetic Surgery Journal*, 40(1), 66–76. <https://doi.org/10.1093/asj/sjz156>