

Surgical Management of Dupuytren's Disease: A Case Series of 27 Patients

H. Sqalli Houssaini^{1*}, I. Moustakbal¹, S. Ezzaim¹, O. Imani¹, J. Hafidi¹, N. Gharib¹, A. Abbassi¹, S. El Mazouz¹

¹Plastic and Reconstructive Surgery Department, CHU Ibn Sina Rabat, Morocco

*Corresponding author: H. Sqalli Houssaini

Plastic and Reconstructive Surgery Department, CHU Ibn Sina Rabat, Morocco

Article History

Received: 27-06-2025

Accepted: 28-08-2025

Published: 02-09-2025



Abstract:

This retrospective study aims to evaluate the clinical outcomes and postoperative complications associated with the surgical management of Dupuytren's disease, through the analysis of 34 procedures performed in 27 patients at CHU Ibn Sina in Rabat between May 2021 and May 2024. Two surgical techniques were used: regional selective fasciectomy (70.5%) and dermofasciectomy with or without skin grafting (29.4%). Most patients presented with stage II or III disease based on Tubiana's classification. After a mean follow-up of 48.2 months, 85.3% of cases demonstrated good to excellent functional outcomes. The overall complication rate was low, including cases of infection, transient hypoesthesia, delayed wound healing, and one nerve injury that was successfully repaired. The recurrence rate was 5.9%. These findings confirm the efficacy of selective fasciectomy in advanced disease stages, with outcomes consistent with the literature. Minimally invasive approaches such as percutaneous aponeurotomy or collagenase injection may serve as alternatives in selected patients.

Keywords: Dupuytren's disease, Selective fasciectomy, Dermofasciectomy, Surgical outcomes, Hand surgery.

Case Report

Copyright © 2025 The Author(s): This is an open-access article distributed under the terms of the Creative Commons Attribution 4.0 International License (CC BY-NC 4.0) which permits unrestricted use, distribution, and reproduction in any medium for non-commercial use provided the original author and source are credited.

INTRODUCTION

Dupuytren's disease is a benign fibroproliferative disorder of the hand that progressively leads to irreversible flexion contractures, mainly affecting the ring and little fingers, with significant functional impairment. First mentioned by Felix Plater in 1614, the condition was fully described in 1831 by Guillaume Dupuytren, who identified its aponeurotic origin and introduced the earliest surgical techniques. Although the etiology remains uncertain, recognized risk factors include male sex, advanced age, alcohol consumption, smoking, and genetic predisposition.

Management strategies range from conservative to surgical. Collagenase injections and percutaneous aponeurotomy offer minimally invasive options but are typically reserved for early-stage disease due to their high recurrence rates. Selective fasciectomy or dermofasciectomy

is the gold standard in more advanced cases, providing better long-term disease control.

This article presents our experience managing 27 cases of Dupuytren's disease and includes a review of the relevant literature.

Patients and Methods

This retrospective study included patients diagnosed with Dupuytren's disease and treated in the Plastic and Reconstructive Surgery Department of CHU Ibn Sina, Rabat, from May 2021 to May 2024.

Disease staging was based on the Tubiana classification (Figure 1), taking into account the number of affected digits per hand. Family history, personal habits (smoking, alcohol consumption), medication usage, and comorbidities were documented for all patients.

Informed consent was obtained from all patients. Procedures were performed under infraclavicular block anesthesia with tourniquet application. Prophylactic amoxicillin/clavulanic acid was administered 24 hours before and after surgery.

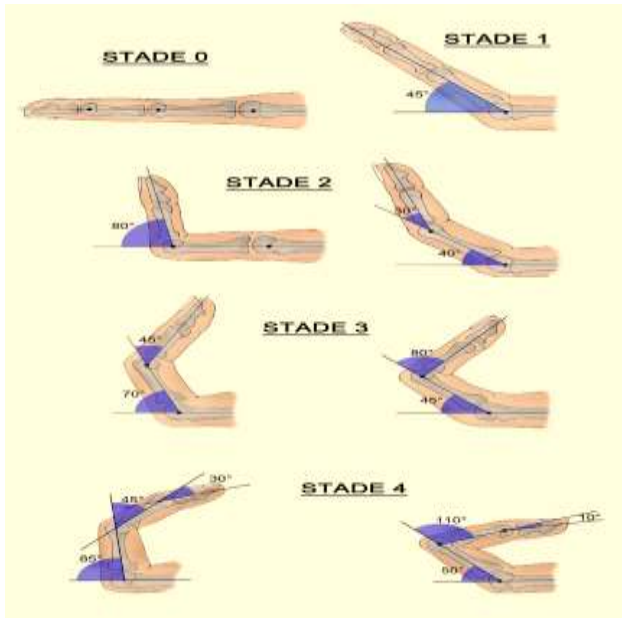


Figure 1: Tubiana Classification

- **Stage 0:** No lesion, normal hand
- **Stage N:** Presence of a palmar or digital nodule without established flexion deformity
- **Stage 1:** Total flexion deformity between 0° and 45°
- **Stage 2:** Total flexion deformity between 45° and 90°
- **Stage 3:** Total flexion deformity between 91° and 135°
- **Stage 4:** Total flexion deformity greater than 135°

Two surgical approaches were used:

- Selective fasciectomy, with zigzag incision or straight incision with Z-plasties, involved excising pathological aponeurotic tissue while preserving neurovascular bundles and the overlying skin.
- Dermofasciectomy, involving en bloc resection of fibrotic aponeurosis and infiltrated skin, was followed by directed wound healing or skin grafting.

A postoperative splint maintained finger extension. Physical therapy was

initiated early, and nighttime splinting continued for three months.

Patients underwent regular follow-up to assess outcomes and complications. Results were classified into four categories according to Khan *et al.*,

- Excellent: full recovery without recurrence
- Good: minor limitation without functional impact
- Fair: joint stiffness affecting daily activities
- Poor: severe functional loss without recovery after the initial contracture

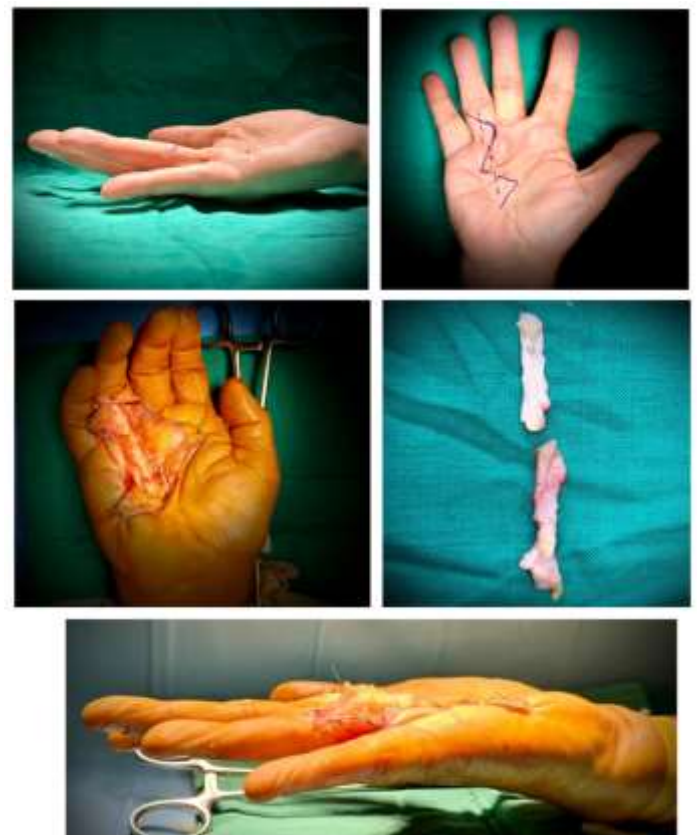


Figure 2: A 57-year-old patient presenting with stage II Dupuytren's disease affecting the ring finger (D4); a selective fasciectomy was performed through a zigzag incision, with excision of the fibrous cord and full restoration of finger extension"

RESULTS

The mean patient age was 59.8 years (range: 41–86 years). Nine patients were regular smokers; three consumed alcohol habitually. Five were diabetics on oral therapy.

A total of 34 hands in 27 patients (22 men and 5 women) were operated on. Bilateral involvement was observed in 7 patients (25.7%).

According to the Tubiana classification:

- Stage N: 5 hands (11.8%)
- Stage I ($\leq 45^\circ$ flexion): 10 hands (29.4%)
- Stage II (45° – 90°): 15 hands (44.1%)
- Stage III (91° – 135°): 4 hands (14.7%)

Regarding digital involvement:

- 15 hands had two affected fingers
- 6 had three affected fingers
- 13 had a single finger involvement

Surgical technique distribution:

- 24 hands (70.5%) underwent selective fasciectomy
- 10 hands (29.4%) underwent dermofasciectomy

Complications included:

- Surgical site infection: 2 cases (5.9%)
- Local skin necrosis: 1 case (2.9%)
- Transient hypoesthesia: 3 cases (8.8%)
- Delayed wound healing: 4 cases (11.8%)

There were two cases of recurrence, both in patients treated with selective fasciectomy. One intraoperative injury to the digital radial nerve of the fifth finger occurred and was successfully repaired microsurgically.

Follow-up duration averaged 48.2 months (range: 24–86 months). Functional outcomes were as follows:

- Excellent: 14 hands (41.2%)
- Good: 15 hands (44.1%)
- Fair: 5 hands (14.7%)

DISCUSSION

Dupuytren's disease remains a surgical challenge due to its chronic fibroproliferative nature and variable recurrence risk depending on treatment modality. Our study highlights the predominance of advanced disease stages and the effectiveness of selective fasciectomy in our patient population.

Outcomes were encouraging, with 85.3% of patients achieving good to excellent results and a recurrence rate of 5.9%, consistent with findings from Khan *et al.*, (97% success at 5 years). Complication rates were within the reported ranges for open surgical techniques.

Open fasciotomy may offer a less invasive alternative, especially in elderly or fragile patients. While technically simpler and often well-tolerated, it has a higher recurrence rate due to incomplete excision of pathological tissue.

Other minimally invasive options include:

- Needle aponeurotomy, performed outpatient with a needle under passive extension. Effective for MCP contractures but limited for PIP joints, with recurrence up to 85% at 5 years (Van Rijssen *et al.*).
- Collagenase *Clostridium histolyticum*, withdrawn in several countries, enzymatically dissolves the cord. It is effective for MCP contractures but less so for PIP. High cost and side effects limit widespread use.

Selective fasciectomy remains the treatment of choice for moderate to severe forms, particularly in hospital settings. Microsurgical tools are recommended due to the cord's anatomical proximity to neurovascular bundles.

CONCLUSION

Selective fasciectomy proves to be a reliable and effective surgical treatment for moderate to severe Dupuytren's disease, offering good disease control with minimal complications. Less invasive options—open fasciotomy, needle aponeurotomy, and collagenase injections—may be suitable in selected patients, particularly those unfit for more extensive procedures. Treatment choice should be individualized based on disease stage, patient expectations, and available resources.

Statements

Conflict of Interest: The authors declare no conflict of interest.

Patient Consent: Informed consent was obtained from all individual participants included in the study.

REFERENCES

- Dolmans, G. H., Werker, P. M., Hennies, H. C., Furniss, D., Festen, E. A., Franke, L., ... & Wijmenga, C. (2011). Wnt signaling and Dupuytren's disease. *New England Journal of Medicine*, 365(4), 307-317.
- Khan, P. S., Iqbal, S., Zaroo, I., & Hayat, H. (2010). Surgical treatment of Dupuytren's contracture; results and complications of surgery: our experience. *Journal of hand and microsurgery*, 2(02), 62-66.
- Aykut, S., Baydar, M., Büyük, A. F., Öztürk, İ. A., Özden, E., & Öztürk, K. (2017). Surgical treatment results for dupuytren's disease. *Acta Ortopedica Brasileira*, 25(3), 71-73.
- Hurst, L. C., Badalamente, M. A., Hentz, V. R., Hotchkiss, R. N., Kaplan, F. T., Meals, R. A, *et al.*, (2021). Dupuytren contractures: current review. *J Hand Surg Am*, 46(10), 896.e1–896.e7.
- Bainbridge, C., Dahlin, L. B., Szczypa, P. P., Cappelleri, J. C., Guérin, D., & Gerber, R. A. (2012). Current trends in the surgical management of Dupuytren's disease in Europe: an analysis of patient charts. *Eur J Plast Surg*, 35(6), 469–476.